

# Screening of Diabetic Retinopathy using a non-mydriatic fundus camera and the artificial intelligence software

Ilavská Linda <sup>(1,3)</sup>, Bražinová Alexandra <sup>(2)</sup>

<sup>1</sup> Faculty of Medicine, Comenius University Bratislava, Slovakia

<sup>2</sup> Faculty of Medicine, Comenius University Institute of Epidemiology, Bratislava, Slovakia

<sup>3</sup> Out-patient Department of Diabetology, Medispektrum s.r.o., Bratislava, Slovakia



## INTRODUCTION

About one in three people with diabetes over the age of 40 already show some signs of diabetic retinopathy. Lifelong repetitive examination is essential for the early detection of microvascular eye complications. Digital non-mydriatic cameras using artificial intelligence software increase the availability of diabetic retinopathy screening.

The study focuses on the utilization of modern technologies employing artificial intelligence for the screening of diabetic retinopathy in patients with type 1 and type 2 diabetes mellitus, gestational diabetes, and specific forms of diabetes in routine clinical practice at the Diabetes Out-patient Clinic.

## METHODS

We examined 403 adult diabetics (Table 1) as part of the routine appointment at a Diabetes Outpatient Clinic from January to March 2024.

Table 1 Cohort characteristics

Type of DM	Age	Number of examined by type of DM n (%)	Gender	
			Female n (%)	Male n (%)
DM1T	41	19 (4,7)	7 (36,8)	12 (63,2)
DM2T	69	370 (91,8)	163 (44,1)	207 (55,9)
Gestational diabetes	35	13 (3,2)	13 (100)	0 (0)
Specific forms of DM	68	1 (0,03)	0 (0)	1 (100)
Overall	54,5	403 (100)	183 (45,4)	220 (54,6)

DM – Diabetes Mellitus, DM1T – Diabetes Mellitus Type 1, DM2T – Diabetes Mellitus Type 2

Fundus images were captured with a non-mydriatic camera DRSplus® with a fundus imaging system utilizing TrueColor Confocal technology by iCare, Finland, and the software product RetCAD™ developed by Thirona, the Netherlands, certified as class IIa. The camera and software employ artificial intelligence to analyze color fundus images for the presence of diabetic retinopathy and age-related macular degeneration.

Diabetic patients underwent fundus photography of both eyes using the non-mydriatic DRSplus® fully automated digital camera with a fundus imaging system featuring TrueColor Confocal technology by iCare (Figure 1). Figure 2 shows the sequence of the procedures in the screening examination.

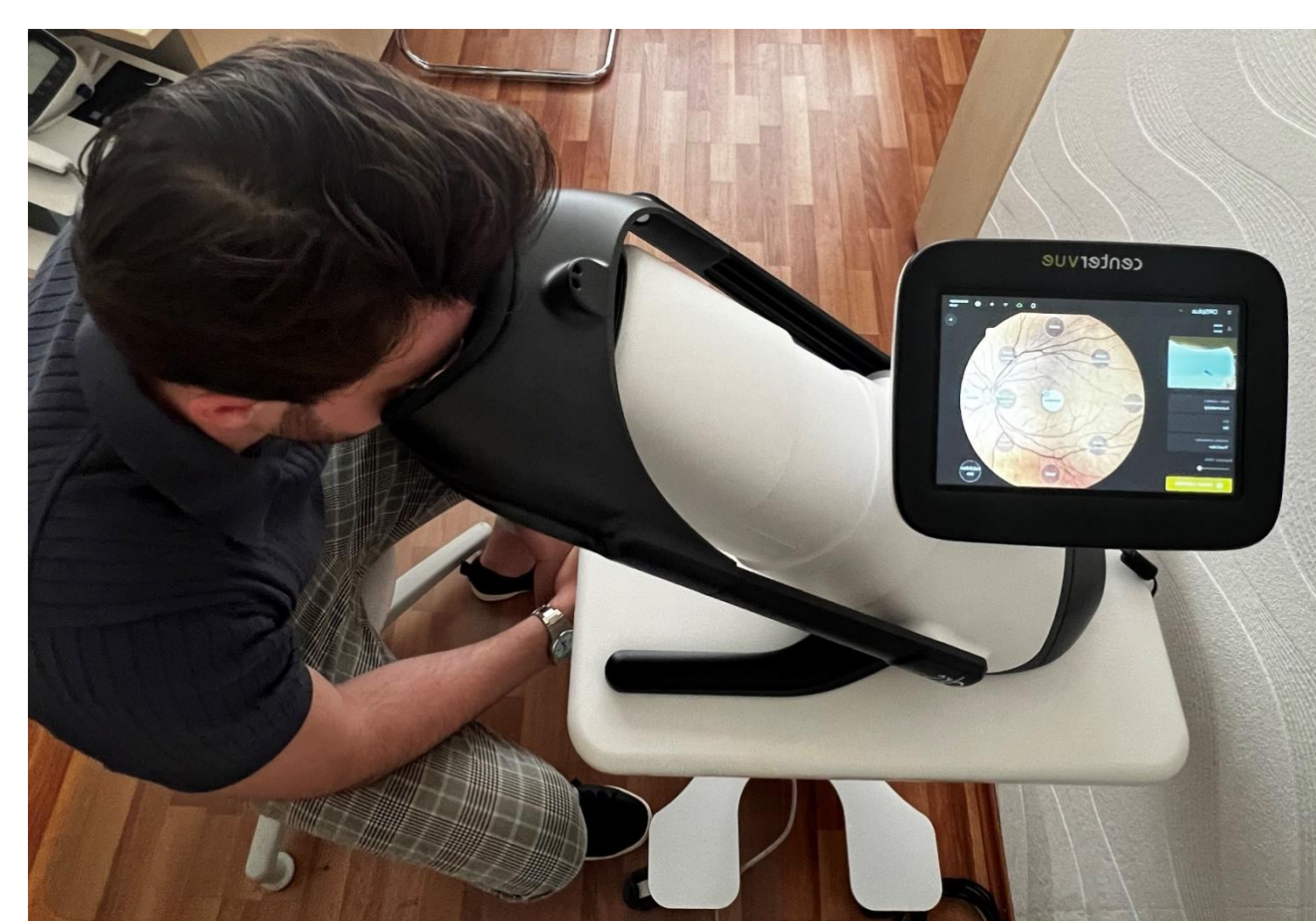

Figure 1 Screening with digital fundus camera

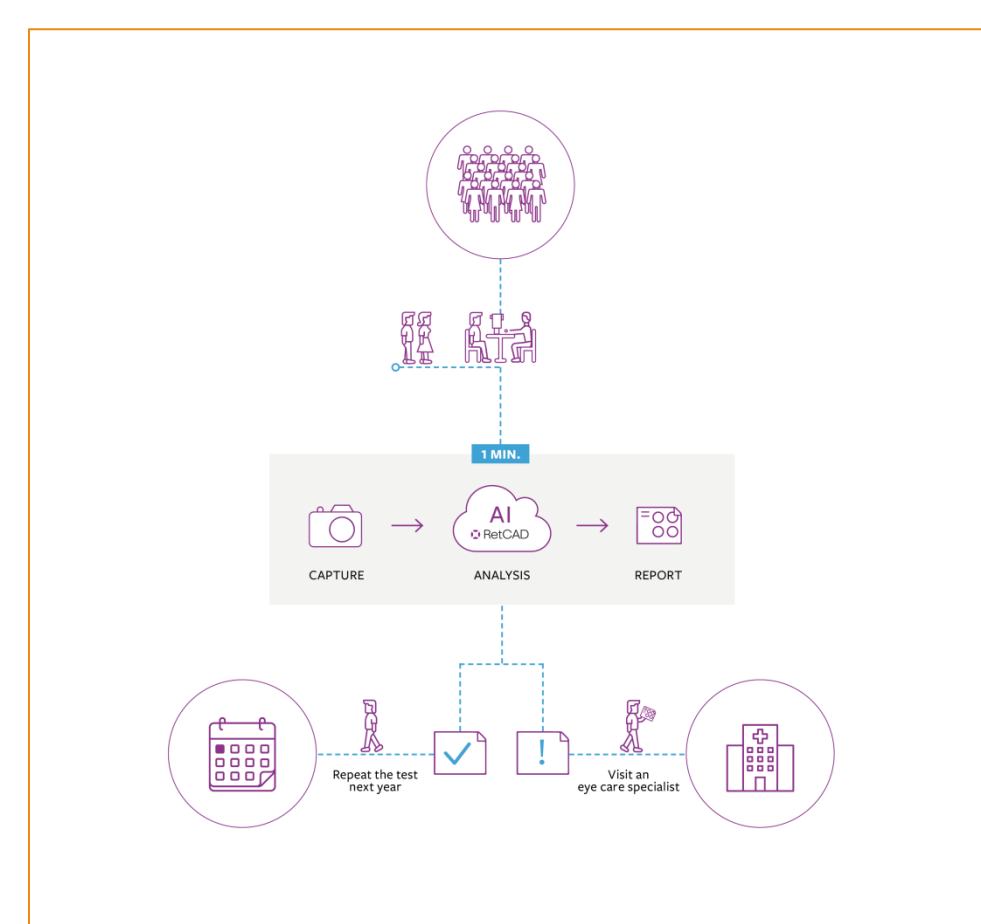


Figure 2 Screening procedures

Good quality retinal imaging of 336 diabetic patients was evaluated. The color images of the retina, two of each eye, were sent via a digital interface, Illume®, by iCare and graded by the RetCAD™ software with artificial intelligence, by Thirona, with class IIa certification (Figure 3). Software system provides results instantly with a score and heat map.

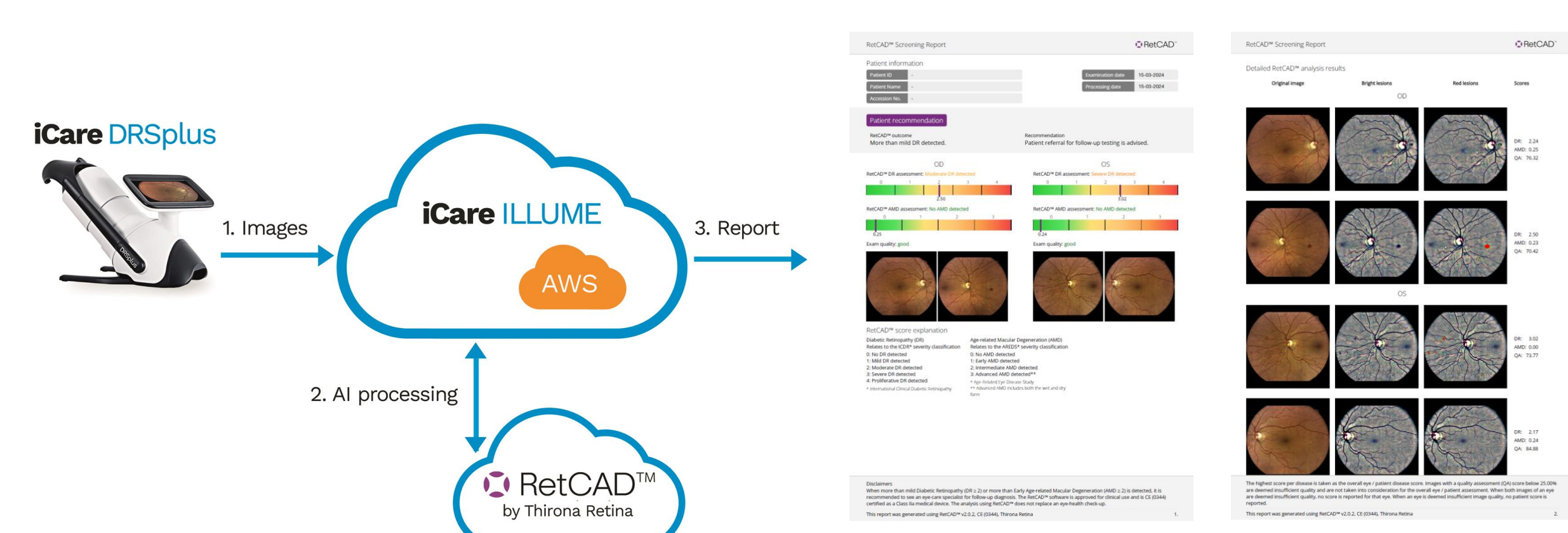


Figure 3 Solution diagram and Screening report

All diabetic patients were referred to ophthalmologists for a regular and complete eye examination, including an evaluation of our results with the artificial intelligence software.

## RESULTS

In the type 1 diabetes mellitus subgroup, diabetic retinopathy was not detected in 8 (44,4%) patients (Figure 4). Mild retinopathy was present in 4 (22,2%) patients, moderate retinopathy in 3 (16,7%), and severe retinopathy in 3 (16,7%). Proliferative diabetic retinopathy was not detected (0%) (Figure 6).

In the type 2 diabetes mellitus subgroup, diabetic retinopathy was not detected in 229 (68,2%) patients (Figure 5). Mild retinopathy was present in 69 (20,5%), moderate retinopathy in 30 (8,9%), severe retinopathy in 8 (2,4%), and proliferative in 0 (0%) patients (Figure 7). No retinopathy was detected in the gestational diabetes and specific forms subgroup (Table 2).

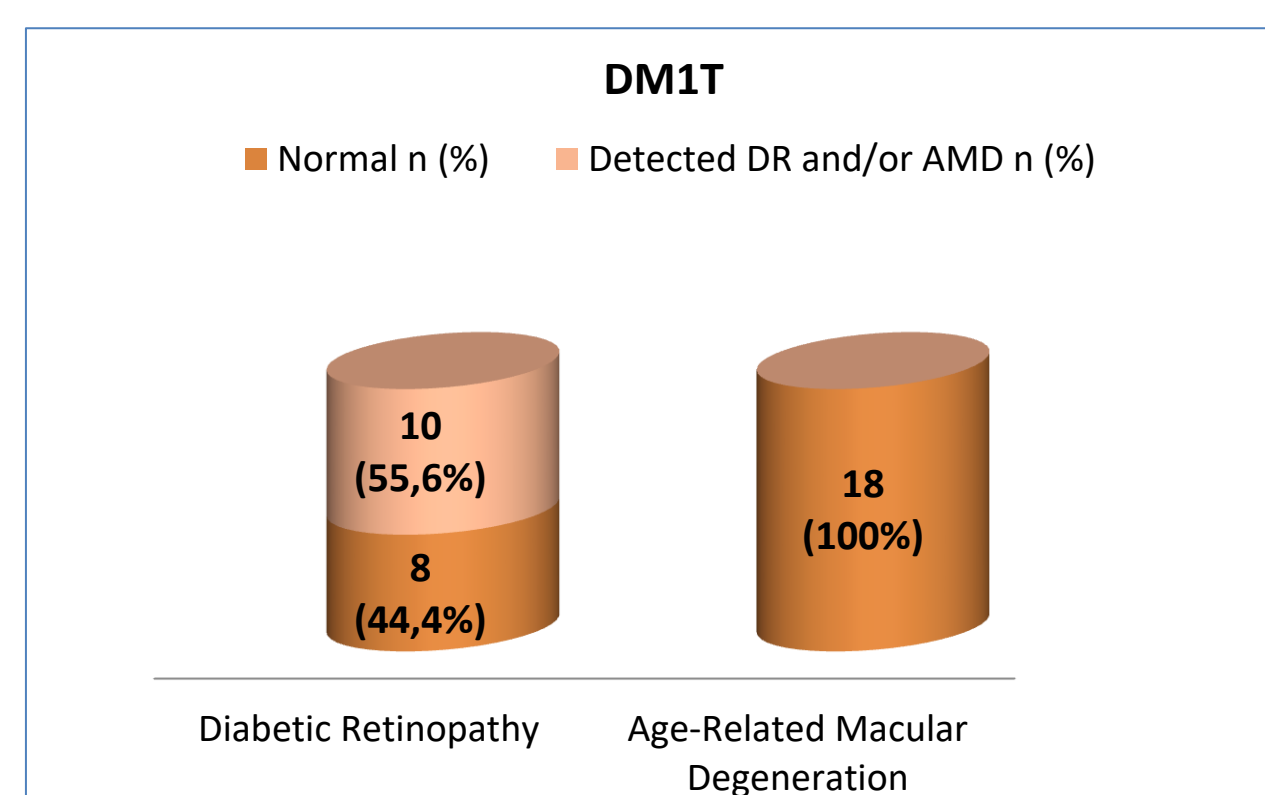


Figure 4 Diabetic retinopathy and Age-Related Macular Degeneration in DM1T

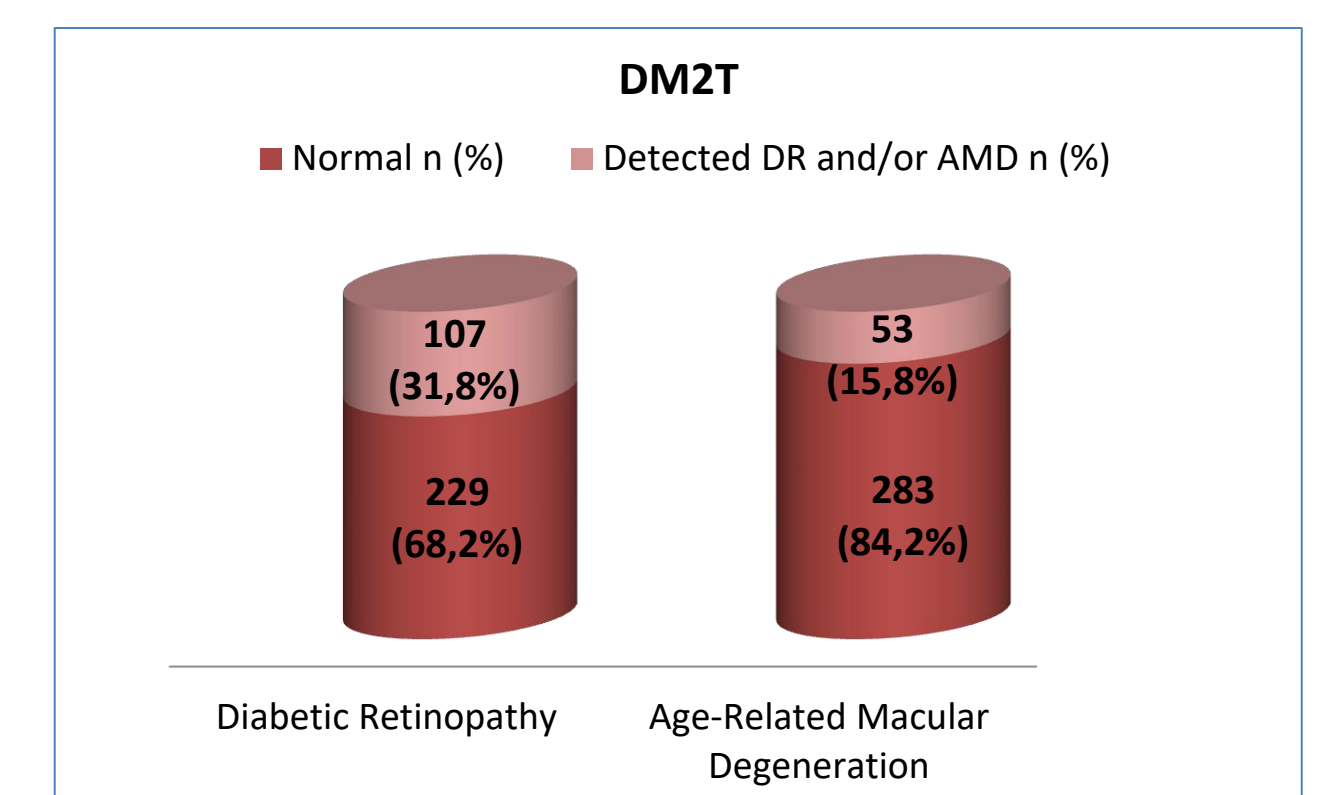


Figure 5 Diabetic Retinopathy and Age-Related Macular Degeneration in DM2T

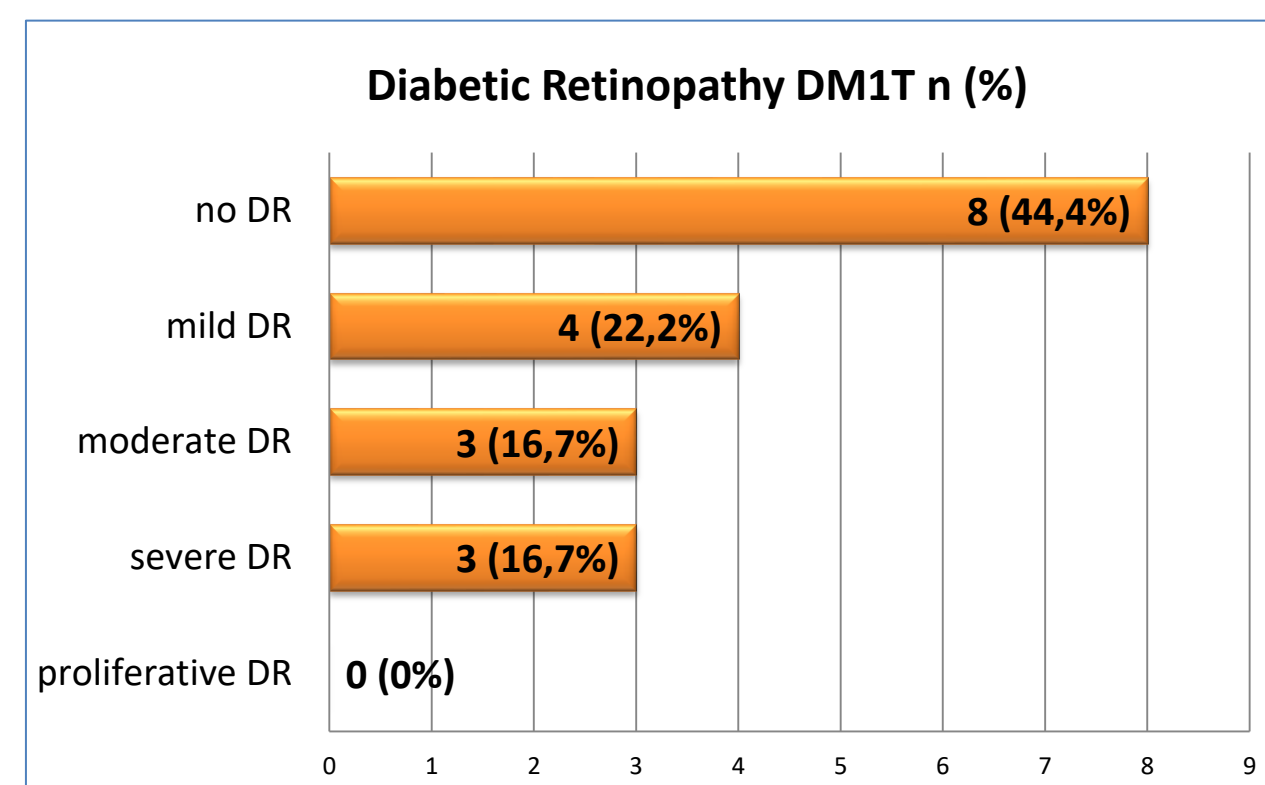


Figure 6 Diabetic Retinopathy in DM1T, ICDR severity classification

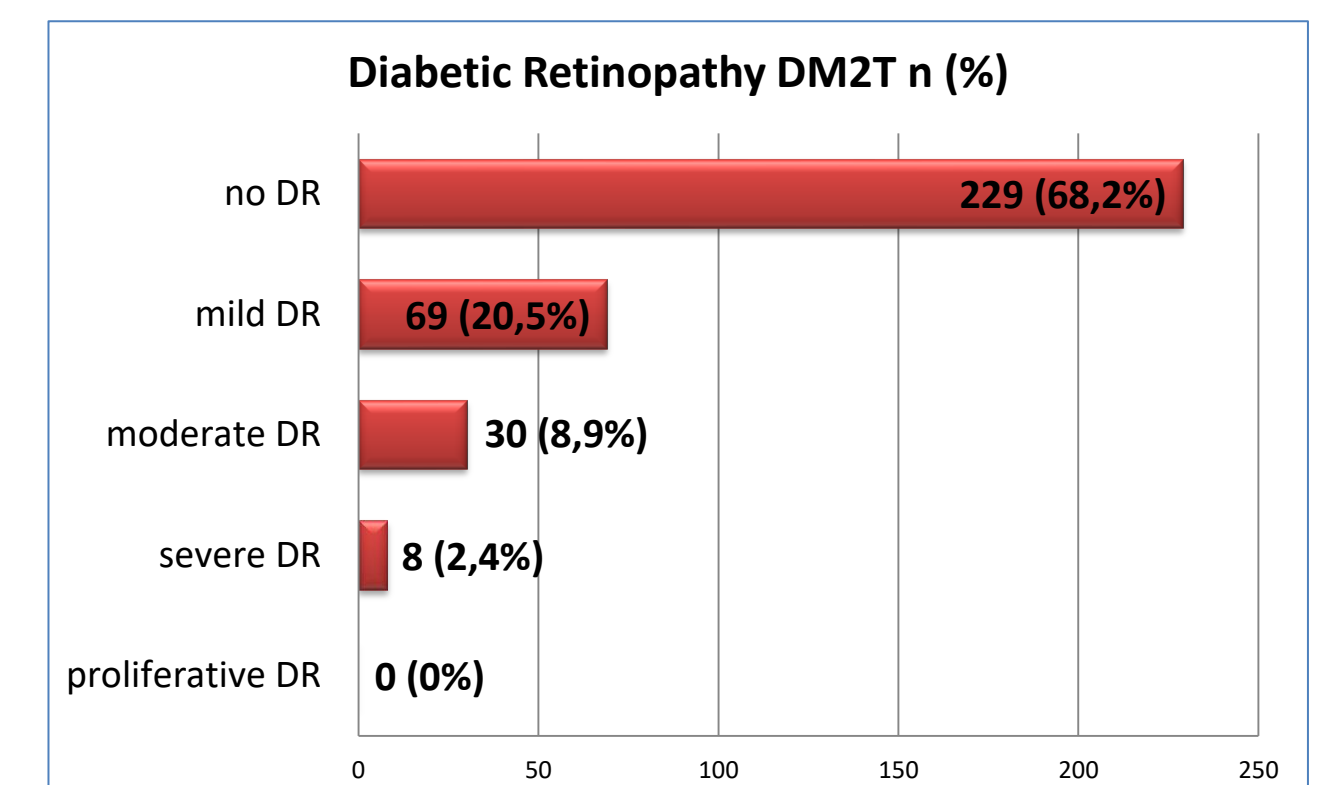


Figure 7 Diabetic Retinopathy in DM2T, ICDR severity classification

Table 2 Results of the eye examinations

Type of DM	DM1T	DM2T	GDM	Specific forms of DM
Number of examined by type of DM	19	370	13	1
Number of examined by type of DM n (%)	18 (100)	336 (100)	13 (100)	1 (100)
DR OS (ICDR)	No DR	8 (44,4)	229 (68,2)	13 (100)
	Mild DR	4 (22,2)	69 (20,5)	0 (0)
	Moderate DR	3 (16,7)	30 (8,9)	0 (0)
	Severe DR	3 (16,7)	8 (2,4)	0 (0)
	Proliferative DR	0 (0)	0 (0)	0 (0)
DR OD (ICDR)	No DR	10 (55,6)	235 (69,9)	13 (100)
	Mild DR	4 (22,2)	64 (19,1)	0 (0)
	Moderate DR	2 (11,1)	28 (8,3)	0 (0)
	Severe DR	2 (11,1)	9 (2,7)	0 (0)
	Proliferative DR	0 (0)	0 (0)	0 (0)
AMD OS (AREDS)	No AMD	18 (94,7)	283 (84,2)	13 (100)
	Early AMD	0 (0)	36 (10,7)	0 (0)
	Intermediate AMD	0 (0)	11 (3,3)	0 (0)
	Advanced AMD	0 (0)	6 (1,8)	0 (0)
AMD OD (AREDS)	No AMD	18 (94,7)	295 (87,8)	13 (100)
	Early AMD	0 (0)	25 (7,4)	0 (0)
	Intermediate AMD	0 (0)	12 (3,6)	0 (0)
	Advanced AMD	0 (0)	4 (1,2)	0 (0)

DM – Diabetes Mellitus, DM1T – Diabetes Mellitus Type 1, DM2T – Diabetes Mellitus Type 2, GDM – Gestational Diabetes Mellitus, DR – Diabetic Retinopathy, AMD – Age-related Macular Degeneration, ICDR – International Clinical Diabetic Retinopathy severity classification, AREDS – Age-Related Eye Disease Study, OS – oculi sinistri, left eye, OD – oculi dextri, right eye

## CONCLUSIONS

The technological advancements allowing images captured with a non-mydriatic fundus camera to be sent immediately to an artificial intelligence system for simultaneous evaluation provide quick and reliable support for screening programs and can be easily integrated into routine clinical practice. Color fundus photography is also helpful for documentation.

Our findings confirmed that a fundus camera with automated artificial intelligence algorithms provides a promising solution for the screening, diagnosis, and grading of diabetic retinopathy in routine practice and offers an effective option for the screening, with the possibility of early diagnosis and prevention of severe complications.

## Bibliography

- IDF and IAPB release joint policy brief for the early diagnosis, treatment and prevention of diabetic retinopathy (2024) International Diabetes Federation. Available at: <https://idf.org/news/idf-iapb-dr-policy-brief> (Accessed: 24 Apr 2024).
- Icare DRSplus fundus imaging system is easy to operate (2023) iCare. Available at: <https://www.icare-world.com/product/icare-drsplus/> (Accessed: 03 May 2024).
- Large scale screening programs: Use case (2023) RetCAD. Available at: <https://retcad.eu/large-scale-screening-programs-use-case/> (Accessed: 24 May 2024).

## Acknowledgement

The project was supported by Dôvera Health Insurance Company, Slovakia, as part of the grant program „Fighters for Health“, by the company iCare, Finland and by University Students Grant Program by Tatra banka Foundation, Slovakia.